

# Herbal Nephropathy

Dr Janet Roscoe

Assoc Professor

University of Toronto

# Herbal nephropathy

- Case Report 2006
- 27 year old Chinese Canadian woman (born Hong Kong to Canada age 9)
- Presented age 25 to another nephrologist with “cancer cells in urine” (positive urine cytology) and “cysts in kidney”
- Referred as query atypical ADPKD
- Negative family history
- No visible hematuria

# Herbal nephropathy

- Case report continued
- Initial workup after insurance physical
- Mild hypertension
- Microscopic hematuria
- Treated with Ramipril 5mg po od
- Family history - father died MI age 63
  - aunt colon cancer
  - sib normal

# Herbal nephropathy

- Ultrasound – right kidney 10.1 cm, left 9.2 cm
- Normal cortical thickness
- Increased echogenecity
- 3 small simple cysts
- 1.4 cm lower pole right,
- 1.2 cm lower pole left
- 0.9 cm midpole left

# Herbal nephropathy

- BP on exam 148/108, 148/98
- CT scan - no contrast – no obvious cysts, one area (5mm) increased attenuation
- MRI and A – 1.6 cm cyst lower left kidney, no renal artery stenosis
- Urine protien 0.1 gm per day
- Creatinine clearance 1.4 mls/min

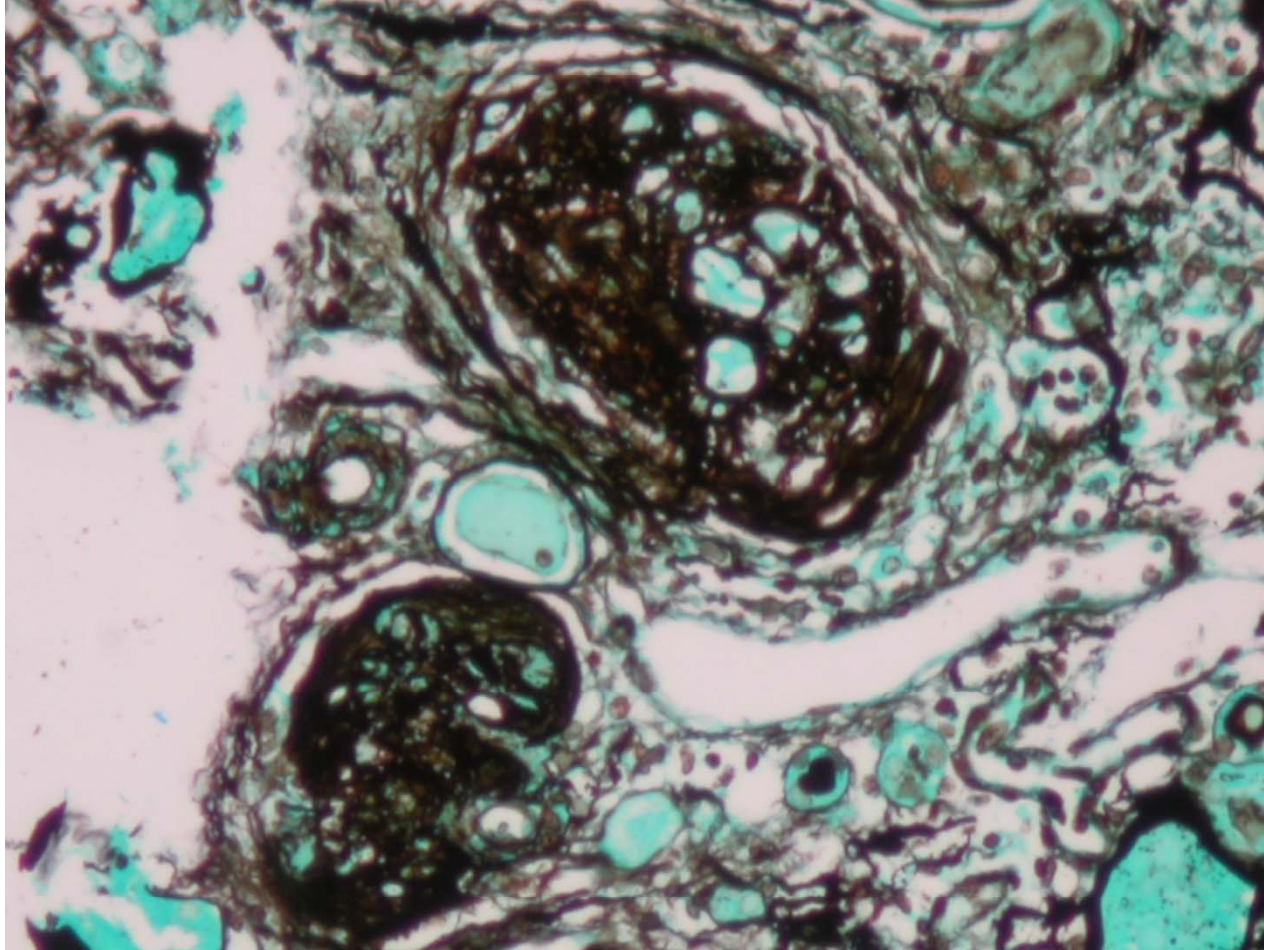
# Herbal nephropathy

- Course
- Creatinine 128 – 120 – 2005
- Creatinine 130-140 – 2007
- Cystoscopy – r/o reflux, negative but a few markedly abnormal urothelial cells, retrograde normal

# Herbal nephropathy

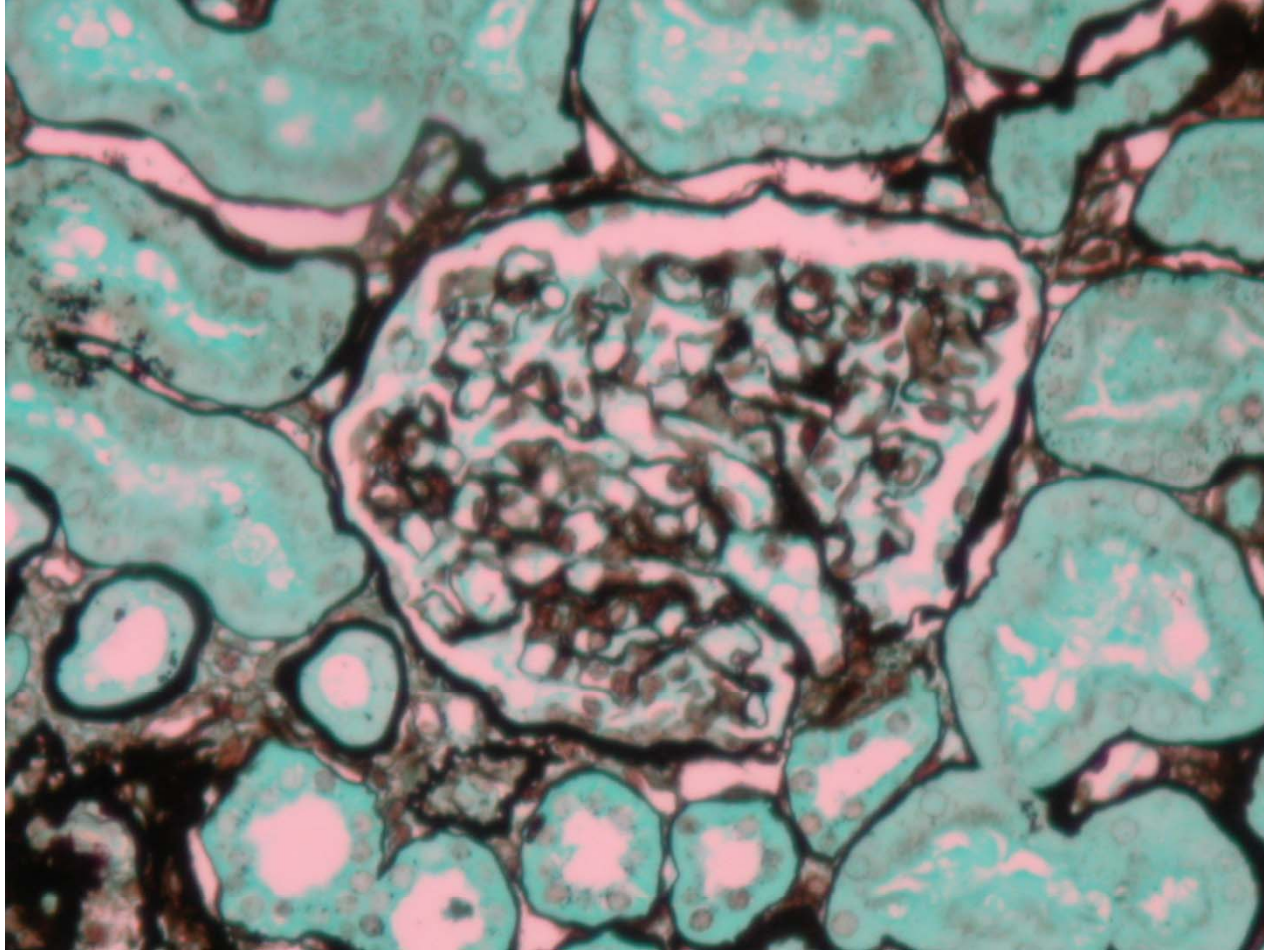
- Renal biopsy April 3, 2008
- 14/21 and 9/15 glomeruli globally sclerosed
- Occasional focal fibrous thickening of Bowman's capsule and dilated thickening of Bowman's space. Glomeruli otherwise normal

# Herbal nephropathy

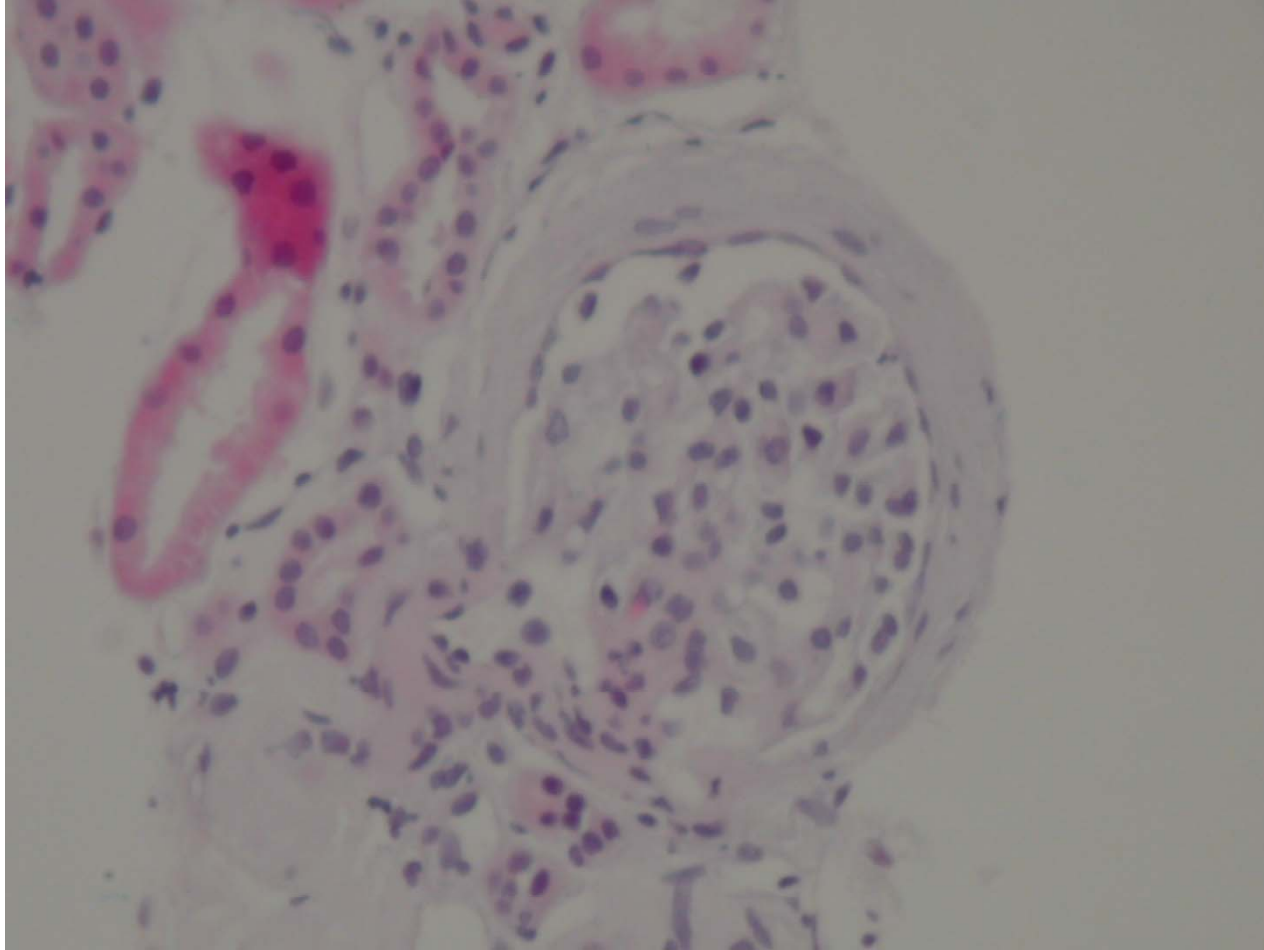




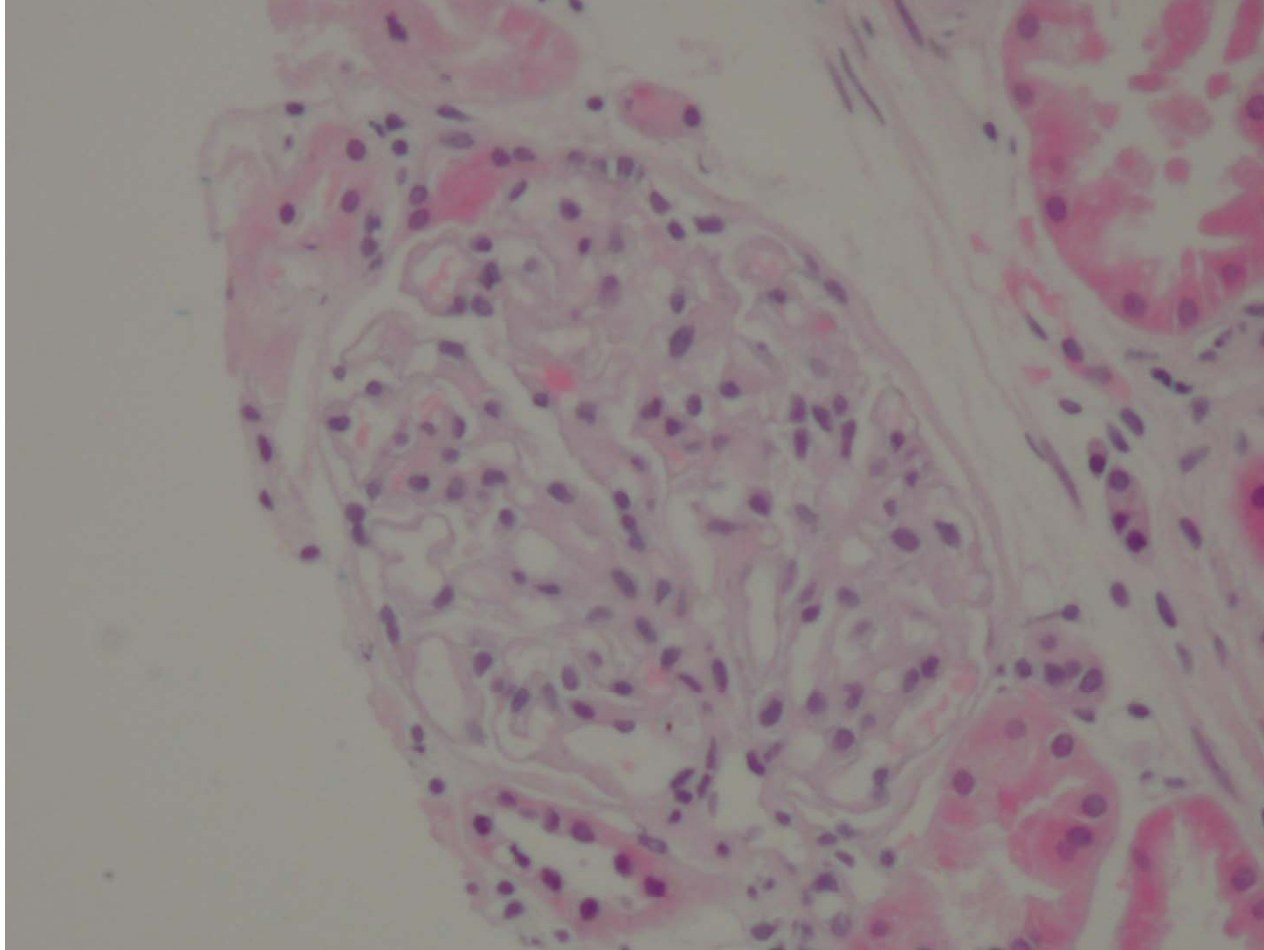
# Herbal nephropathy



# Herbal nephropathy



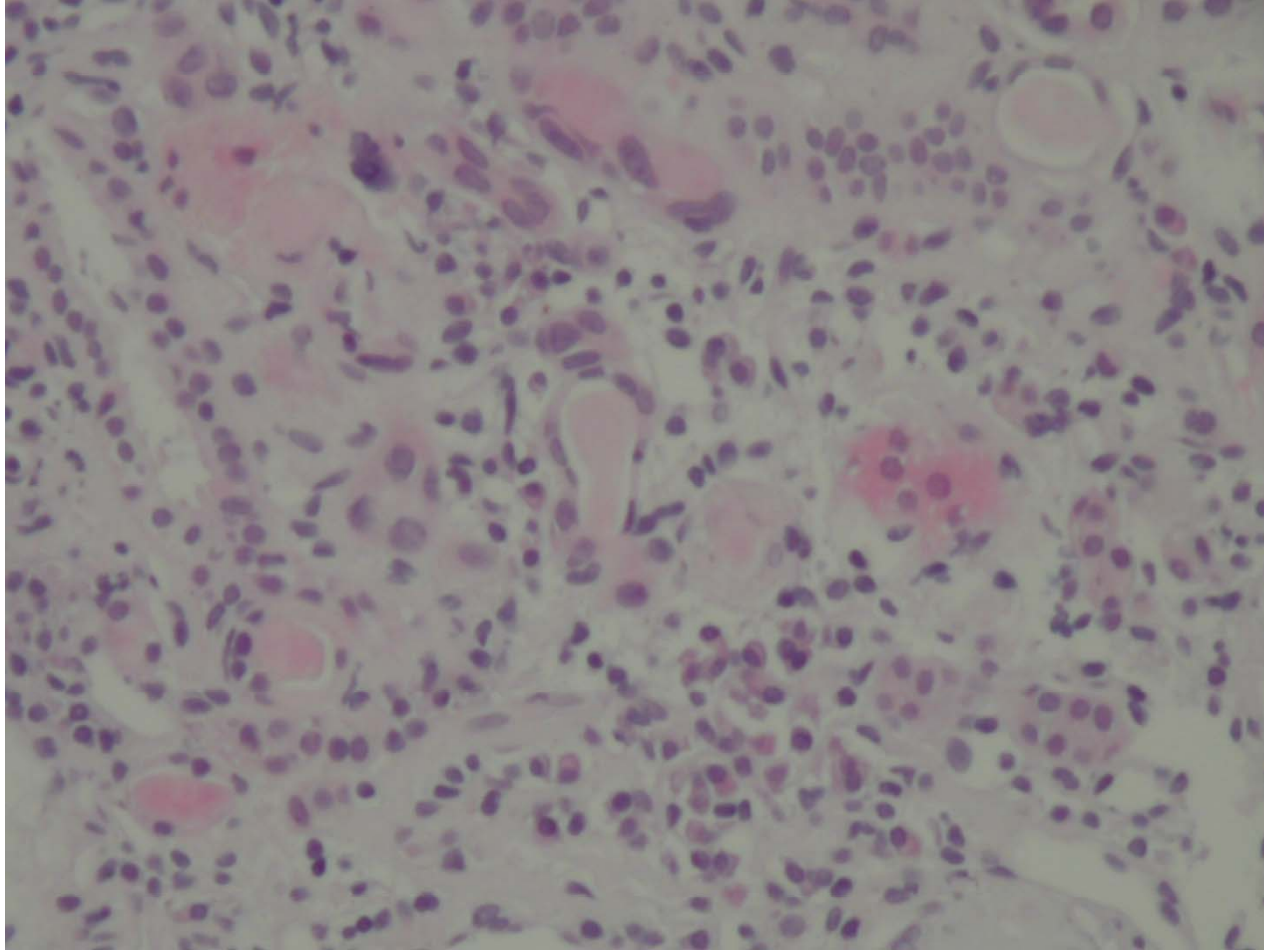
# Herbal nephropathy



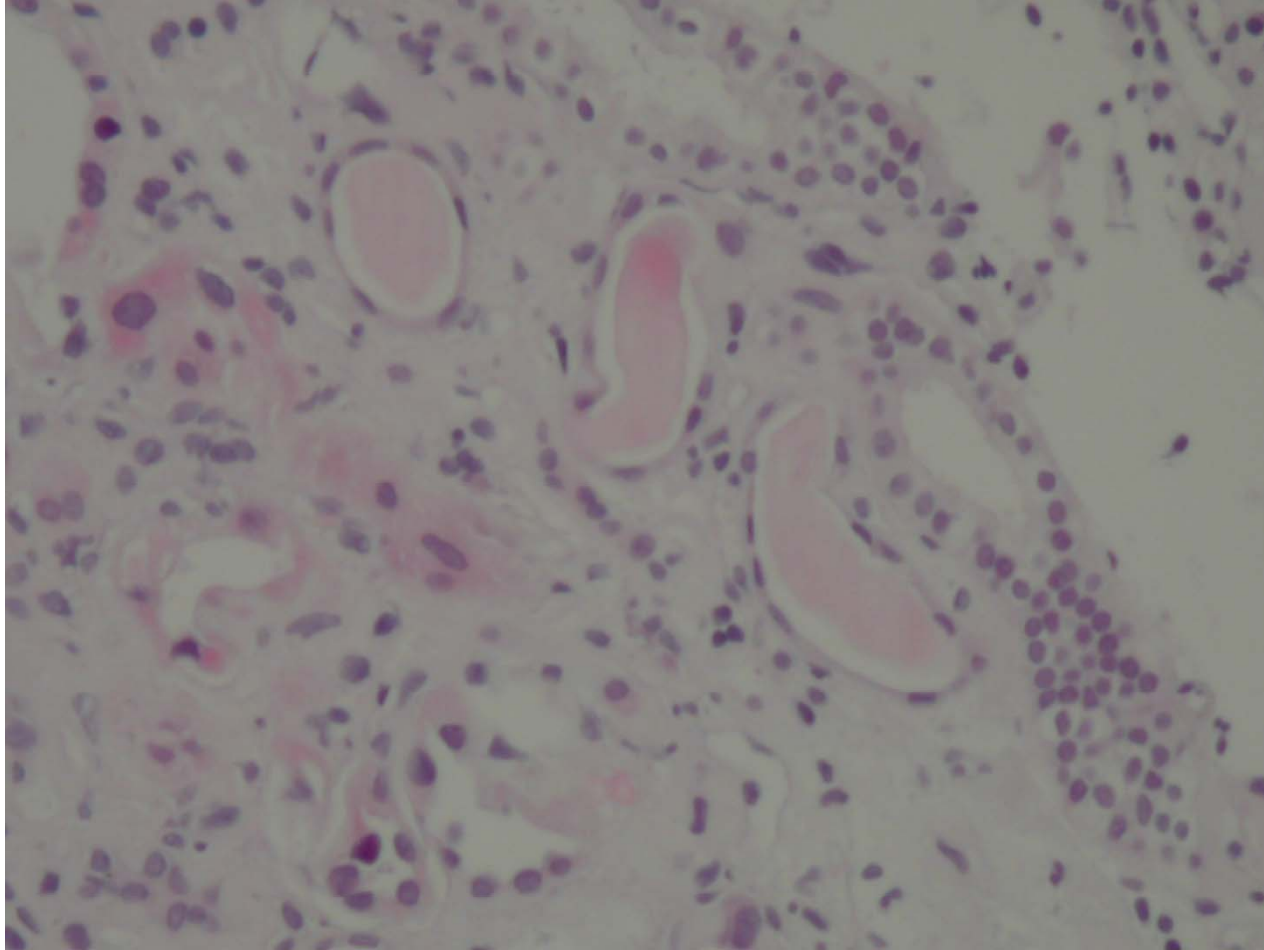
# Herbal nephropathy

- Moderate interstitial fibrosis
- Tubular atrophy
- Patchy inflammatory infiltrate composed of lymphocytes, plasma cells, occasional eosinophils
- Some tubules appeared hypertrophic

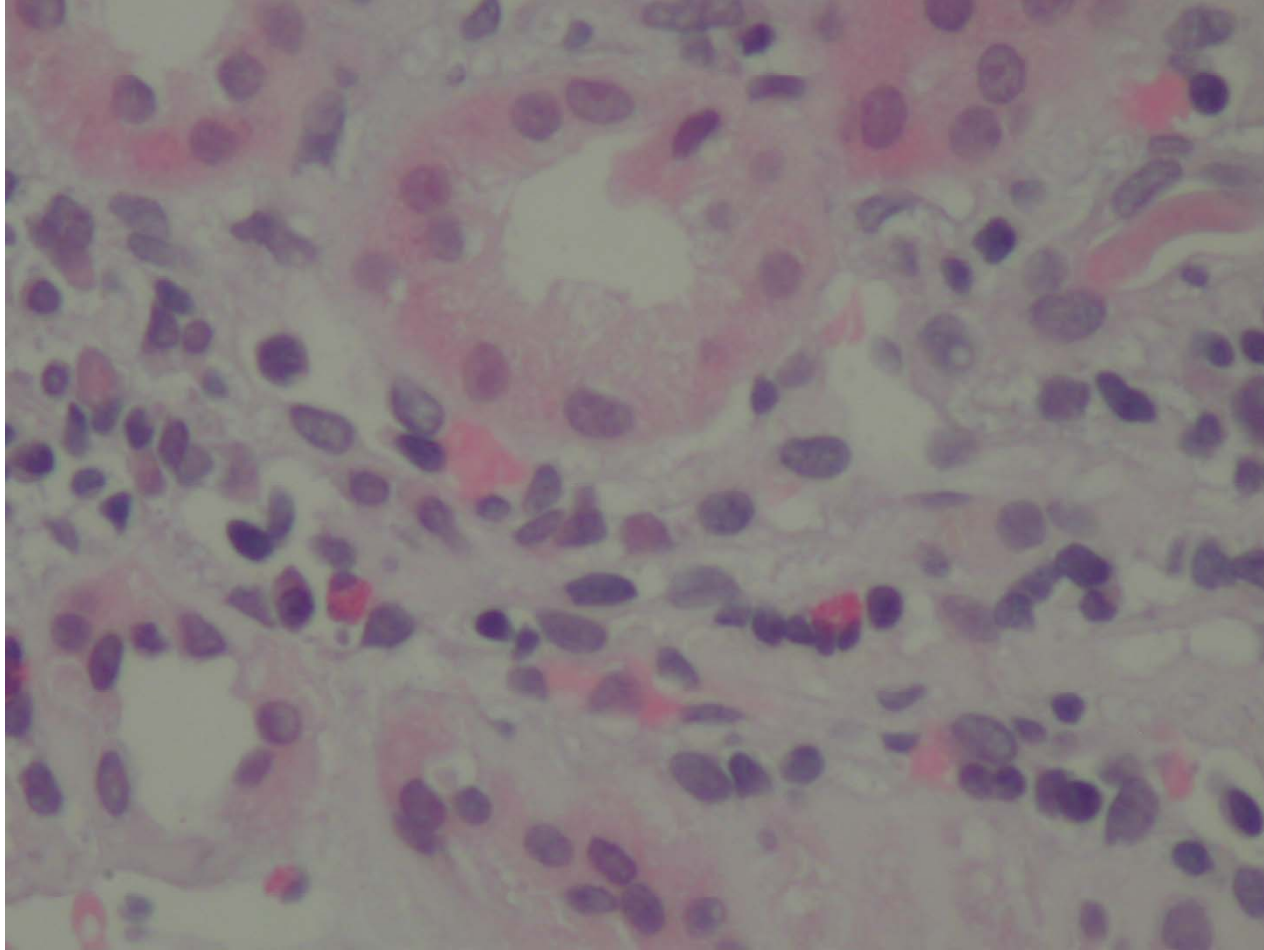
# Herbal nephropathy



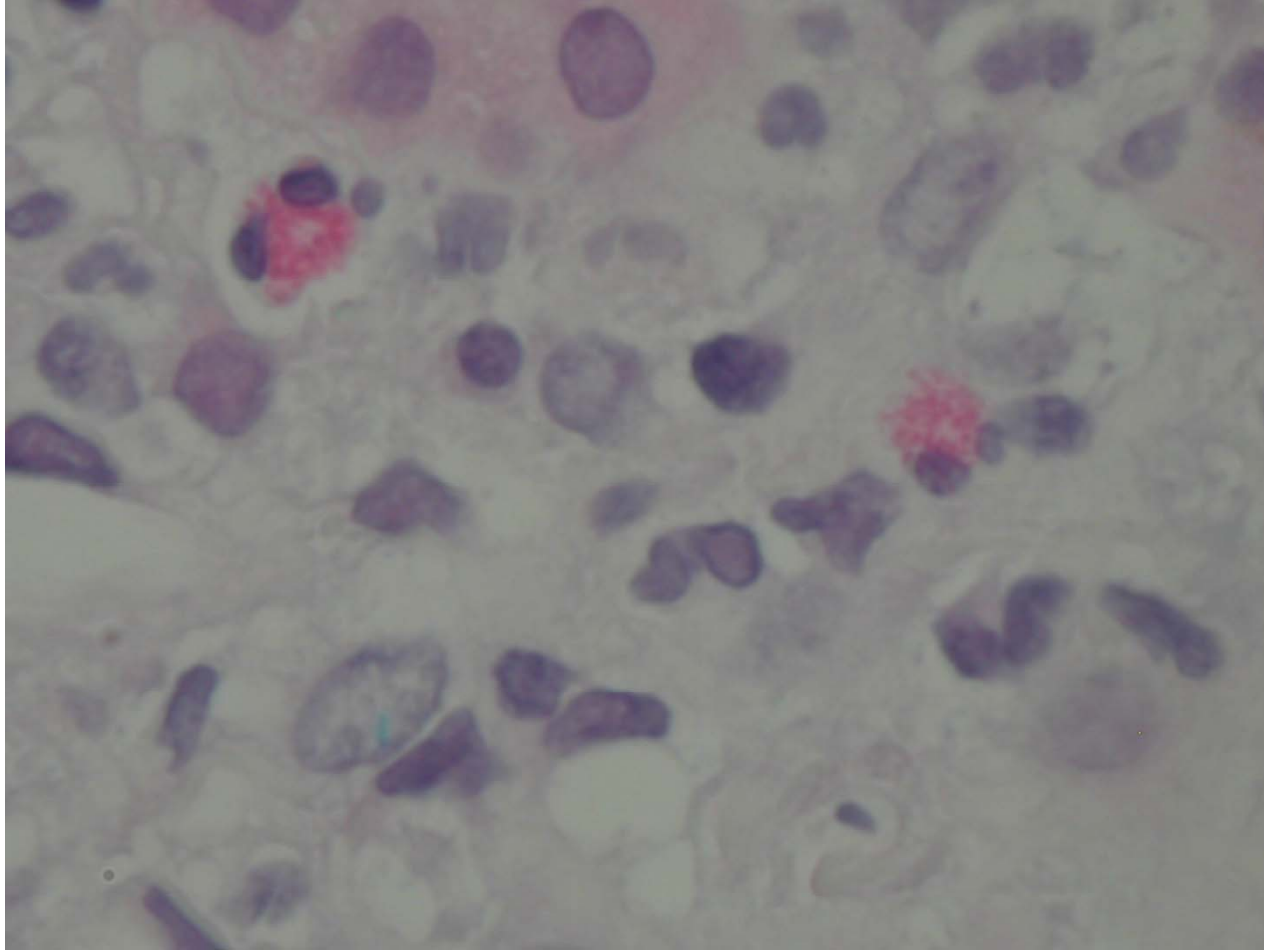
# Herbal nephropathy



# Herbal nephropathy



# Herbal nephropathy

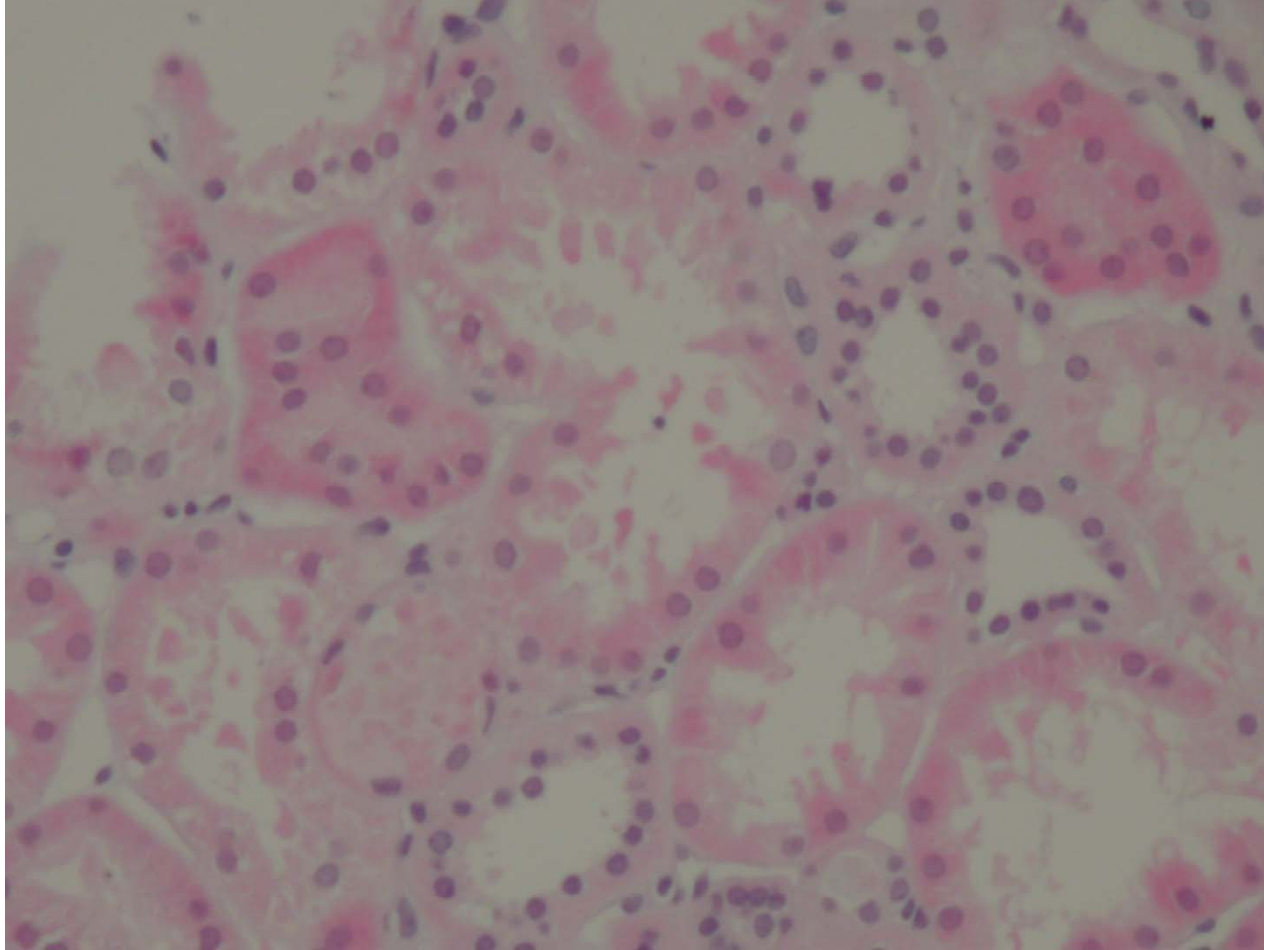




# Herbal nephropathy

- Tubular epithelium showed both degenerative and regenerative changes
- Mild tubular atrophy was present

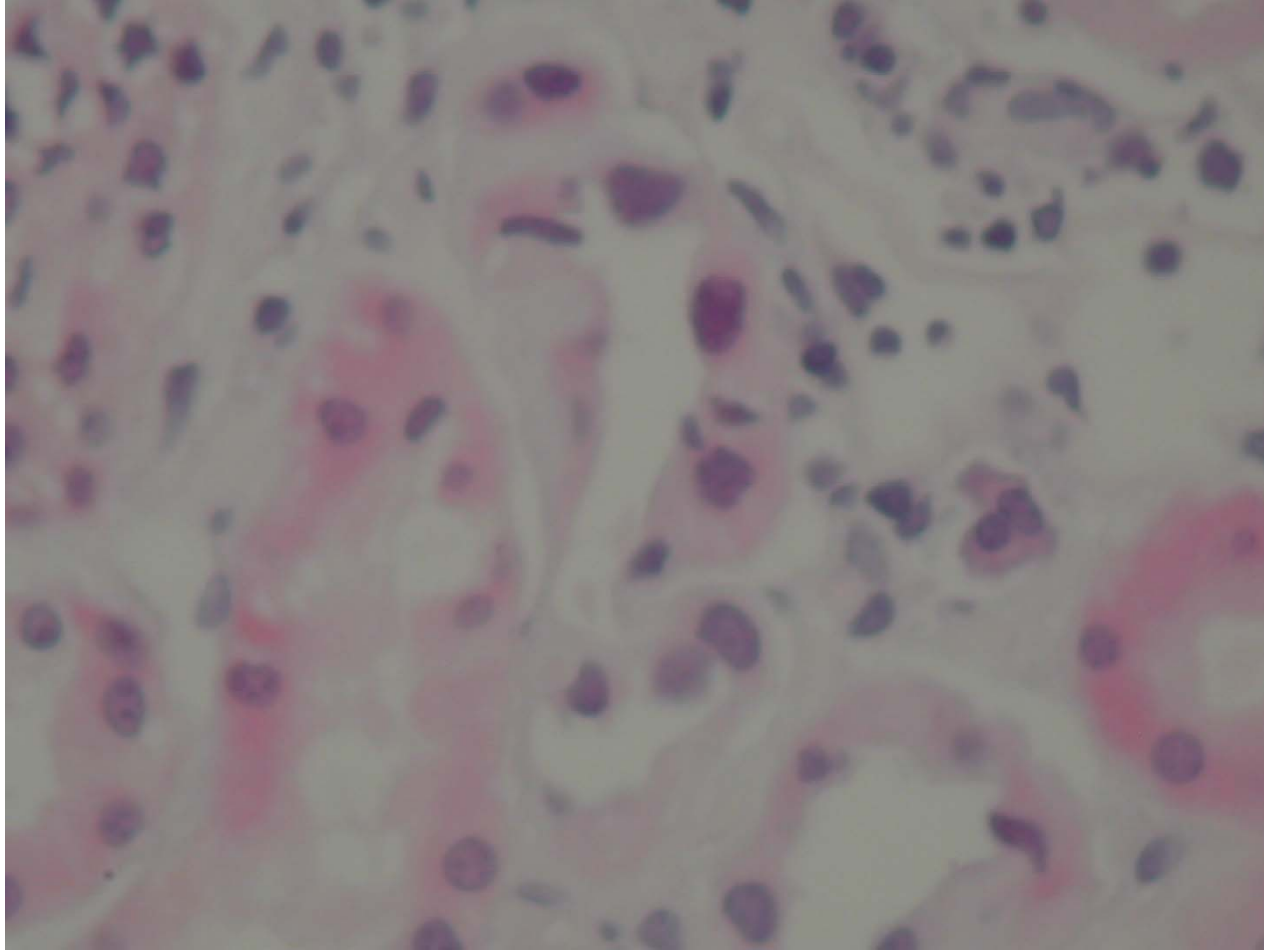
# Herbal nephropathy



# Herbal nephropathy

- Small branch of an arcuate artery showed fibrointimal thickening and has a mucoid appearance
- Mild arteriolar sclerosis

# Herbal nephropathy



# Herbal nephropathy

- Electron microscopy
- Segmental thinning of capillary loops basement membranes
- No electron dense immune deposits, no tubulo-reticular inclusions,
- Mild foot process effacement
- Mild segmental widening of mesangium

# Herbal nephropathy

- Dx – moderate tubulo-interstitial inflammation
- Eosinophils – query drug-induced interstitial nephropathy
- Tried prednisone – tolerated only three weeks – no change

# Herbal nephropathy

- Second opinion
- Focal vascular changes suggest possibility of Chinese-herb nephropathy (CHN)
- Always denied chinese meds but did drink green tea regularly and did use trial of accupuncture
- Later recognized she drank an “elixir” of chinese medicine once a quarter to maintain good health

# Herbal nephropathy

- Followed regularly by urology for transitional cell carcinoma
- CT with TCC protocol Sept 2008, no obvious lesion but increased size and number of lesions of increased attenuation
- Creatinine stable
- BP well controlled



# Herbal Nephropathy

- Also called Aristolochic acid nephropathy (AAN)
- A worldwide problem
- Excellent review article – Kidney International (2008) 74, 158-169 by F. Debelle, JL.Vanherweghem and JL. Nortier

# Herbal Nephropathy

- Rapidly progressive interstitial fibrosis
- Leads to end stage renal disease
- Urothelial malignancy
- Originally reported in Belgium
- Patients ingesting “slimming pills”
- Containing powdered root extracts of Chinese herbs

# Herbal Nephropathy

- Initially called Chinese-Herb nephropathy (CHN)
- Consequence of substitution of “Stephania tetrandra” with “Aristolochia fangchi”
- Both herbs share common name in Pin Yin (Han Fang Ji and Quang Fang Ji)
- One can be used instead of other in traditional Chinese medicine

# Herbal Nephropathy

- Worldwide incidence
- Actual incidence unknown
- Probably underestimated
- Numerous ingredients known or suspected to contain AA are used in traditional medicine in China, Japan and India

# Herbal Nephropathy

- AA hypothesized to be environmental cause of Balkan-endemic nephropathy (BEN)
- Familial chronic tubulointerstitial disease
- Insidious onset
- Slow progression to ESRD
- Increased frequency of urothelial cancer
- Endemic – Serbia, Bosnia, Croatia, Bulgaria, and Romania

# Herbal Nephropathy

- Plants containing AA (known or suspected) still available on Internet

# Herbal nephropathy

- History of AAN
- First recognized in Belgium in 1992
- Two young woman admitted in Brussels with severe interstitial nephritis
- Progressed over a couple of months to ESRD
- Both had followed same weight-loss program in same medical clinic in Brussels one year before

# Herbal nephropathy

- Composition of weight-reducing pills had been modified in June 1990 by adding root extracts from two Chinese herbs – *S. Tetrandia* and *Magnolia officinalis*
- Coincided with unusual increase in incidence of patients with interstitial nephritis of unknown origin admitted for dialysis in Belgium in 1991 and 1992



# Herbal nephropathy

- Survey in Belgium found seven other women patients who had followed same weight loss regimen containing the Chinese herbs
- Belgium authorities banned *S. Tetrandra* and *M. Officinalis* from market in 1992
- Still by 1998 , 100 cases of Chinese-herb nephropathy (CHN) reported in Belgium – 70% in ESRD

# Herbal nephropathy

- Suspected cause soon felt to be inadvertant replacement of *Stephania tetrandra* (Pin Yin name: Han Fang Ji) with *Aristolochia fangchi* (Pin Yin name: Guang Fang Ji)
- Belong to same therapeutic “Fang Ji” family
- Usually traded using common Pin Yin name

# Herbal Nephropathy

- Suspected cause
- Pathologic aspect very similar to Balkan endemic nephropathy (BEN)
- Etiology of BEN controversial
- May be aristolochic acid in *Aristolochia clematitis*

# Herbal nephropathy

- Suspected cause
- Phytochemical analyses of *S. Tetrandra* showed most batches did not contain tetrandrine but aristocholic acid

# Herbal nephropathy

- Survey of 71 cases of CHN patients in Belgium demonstrated in multiple regression analyses that cumulative dose of supposed S.tetrandra (in reality Aristocholic acid) was the only significant factor predicting the fall in creatinine clearance (GFR)
- Causal role confirmed by finding AA DNA adducts in kidney removed from CHN/AAN patients proving prior exposure to AA

# Herbal nephropathy

- AA administered to New Zealand white rabbits or male Wistar rats reproduced interstitial nephritis with the same main histological and functional features of CHN/AAN in the animals
- Term Chinese-herb nephropathy progressively abandoned for term aristocholic acid nephropathy

# Herbal nephropathy

- Similar cases sporadically observed in France, Spain, Germany, United Kingdom, and United States
- Context of herbal remedies for weight loss but also other indications such as eczema, hepatitis B, liver enhancement, arthritis, rheumatism and pain relief

# Herbal nephropathy

- Many cases reported in Asian countries
- Complex traditional pharmacopoeia represents high risk for exposure to AA



# Herbal nephropathy

- Clinical presentation
- Initial presentation usually silent
- Renal failure discovered by routine blood testing
- Some cases present as Fanconi syndrome or acute renal failure due to ATN
- Anemia often more severe than expected for degree of renal failure

# Herbal nephropathy

- Urinary sediment unremarkable
- Dipstick albumin negative
- Marked increase low molecular weight proteins (Beta-2 macroglobulin, cystatin C, Clara cell protein, retinal-binding protein, and alpha-1-microglobulin)
- Other evidence that proximal tubular cells main target of toxicity

# Herbal nephropathy

- Kidneys shrunken
- Asymmetric
- Irregular outlines in 1/3<sup>rd</sup>
- Microscopically – extensive interstitial fibrosis with atrophy
- Loss of proximal tubules mainly in superficial cortex progressing toward the deep cortex

# Herbal nephropathy

- Glomeruli initially spared, later mild collapse of capillaries and wrinkling basement membrane
- Sometimes interstitial inflammatory infiltration
- Led to corticosteroid trial with significant reduction in cases reaching ESRD after one year of steroid therapy
- Reduction in rate of progression confirmed in 8 year followup

# Herbal nephropathy

- Endothelial wall thickening in interlobular and afferent arterioles suggest possible ischaemic process induced by other substances concomitantly administered with the Chinese herb
- Some cases with aortic insufficiency probably related to (dex)fenfluramine

# Herbal nephropathy

- In Western countries outbreaks related to uncontrolled use and uncorrected identification of medicinal herbs – felt to be harmless by public
- In Asia and India AAN is a consequence of complex pharmacopoeia of herbal remedies and lack of regulation (sometimes due to substitution of AA for harmless herb)

# Herbal nephropathy

- Urothelial malignancies
- Cosyns, KI 1994 – moderate atypia and atypical hyperplasia of urothelium (BEN)
- Urothelial carcinoma (Belgium)
- High risk urothelial malignancy – prophylactic removal of native kidneys when on dialysis or transplant

# Herbal nephropathy

- 40-45% of CHN/AAN patients display multifocal high-grade transitional cell carcinomas, mainly in upper urinary tract
- Cumulative ingested dose of Stephania (actually aristolochia) shown to be significant risk for development uroepithelial ca



# Herbal nephropathy

- High incidence bladder carcinoma in followed patients
- greater if prior upper tract malignancy
- Greater incidence in ESRD but can occur sans ESRD